

Implant Site Development by Orthodontic Extrusion of Teeth with Poor Prognosis

GILIANA ZUCCATI, MD, DDS
ANNA BOCCHIERI, MD, DDS

The forced eruption technique was developed by Ingber for treatment of one-wall and two-wall bony pockets that were difficult to handle with periodontal therapy alone.¹ When tension is applied to the periodontal ligament by extrusive forces (provided there is at least a residual periodontal attachment), the periodontal fibers are elongated and osteoblasts are induced to deposit new bone. Brown² and Ingber³ noted that when light forces were used, both the bone and the gingiva of the extruded tooth migrated coronally. Zachrisson pointed out that during the elimination of an intraosseous pocket by orthodontic extrusion, the relationship between the cemento-enamel junction and the bone crest is maintained—in other words, the bone follows the tooth.⁴

Forced orthodontic extrusion of hopeless teeth is reportedly an effective method of augmenting bone in sites where alveolar ridge defects preclude correct implant placement.⁵ As long as at least one-fourth to one-third of the apical attachment remains intact, the attachment apparatus can be used to develop the bone and gingiva in a vertical direction. The tooth is

extracted once the desired change in the ridge shape has been achieved.⁴ The increased volume of the osseous structure will allow the implant to be placed in the correct position, while the soft tissue altered by the forced eruption will match the gingiva around the adjacent natural teeth, or may be surgically adapted to achieve an esthetic appearance.⁵⁻¹⁰

This article illustrates the benefits and limitations of forced eruption in increasing bone volume and improving potential implant sites.

Materials and Methods

Nine teeth in seven patients with advanced periodontal attachment loss were treated with forced extrusion. Five of these patients were undergoing supplemental periodontal therapy, including quarterly scaling and root planing. No bleeding on probing or pocket depths greater than 3mm were noted at the start of treatment. The periodontal defects in two teeth nearly approached the apices, with less than 2mm of bone support on at least one aspect of these roots.

The orthodontic extrusion required three to four months in each patient. Implants were inserted two to four months later, when soft-tissue healing was complete. A typical case is shown below.

Case Report

A 20-year-old female presented with a deep and wide recession with periapical inflammation on her maxillary left central incisor. The patient reported a trauma in the maxillary incisor area at age 8; she had undergone an apicoectomy at age 17, with a bone substitute implanted to fill the periapical osseous lesion.

The buccal recession had reached the post-



Dr. Zuccati

Dr. Bocchieri

Dr. Zuccati is in the private practice of orthodontics at Via Masaccio 173, Florence, 50132, Italy; e-mail: gilzuccati@libero.it. Dr. Bocchieri is in the private practice of orthodontics in Tricesimo, Italy.

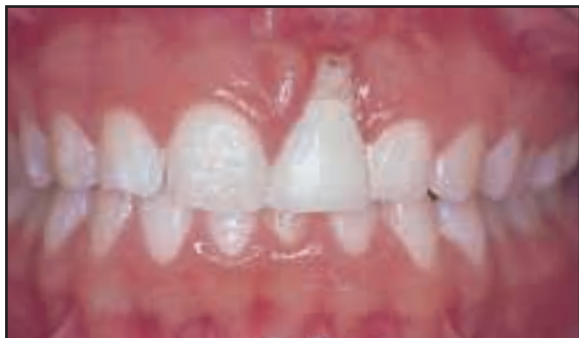

Fig. 1 20-year-old female patient with buccal recession reaching apex of root.

surgical apex of the root (Fig. 1). The buccal gingiva was totally lost, and the mucosa above the recession showed erythema and was painful on palpation. A periodontal probe could be inserted over the apex deep into the space between the surgically modified apex and the surrounding inflamed tissues.

The patient requested an esthetic replacement of the incisor without prosthodontic preparation of the adjacent teeth for a fixed bridge. The tooth had a poor prognosis due to the infection of the foreign body above the large recession. Because the buccal cortex was completely resorbed up to the apex, a Class II deep ridge defect could be anticipated upon extraction, precluding proper placement of an implant. Correction of the defect by regenerative or reconstructive therapy would probably require additional surgery, which the patient wished to avoid. Therefore, a treatment plan involving orthodontic forced eruption was selected.

Edgewise brackets were bonded in the maxillary arch, with the central incisor bracket located more apically to provide an extrusive force (Fig. 2). The patient was seen every two weeks for grinding of the incisal surface of the extruded incisor. After 16 weeks of orthodontic movement, when no enamel remained to hold the central incisor bracket, a small hole was drilled in the buccal root surface of the left central incisor, and a ligature wire was passed through the hole to the extrusive arch to continue the orthodontic movement (Fig. 3).

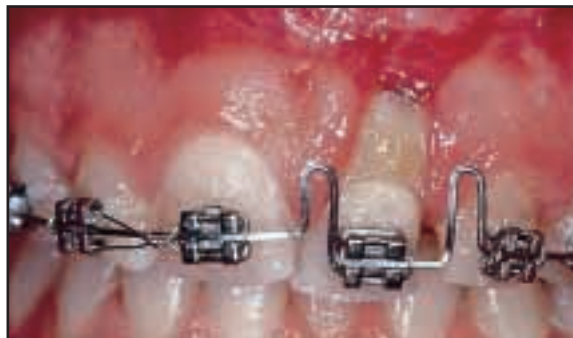

Fig. 2 Orthodontic appliance providing extrusive force and buccal root torque.

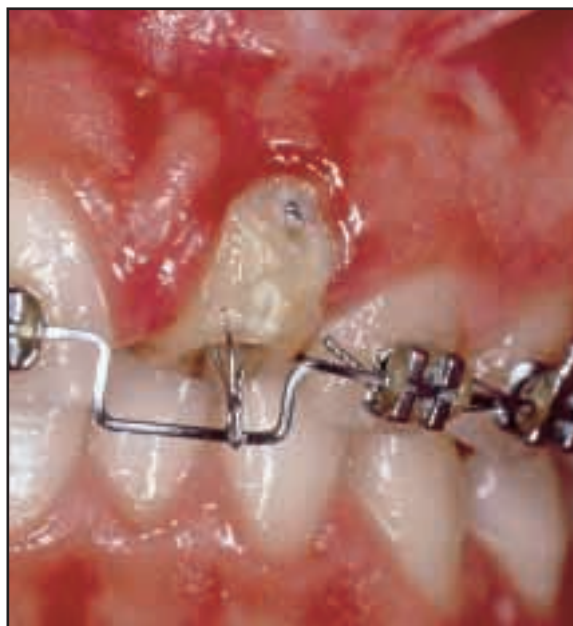

Fig. 3 After 16 weeks of extrusion, ligature wire is passed through small hole in residual root to continue movement.

A light, continuous force produced a vertical downward translation and a rotation in the sagittal plane, with a buccal movement of the apex. The final position of the residual root was almost horizontal at the top of the crest. The buccal marginal tissues followed the movement of the apex, but the change from inflamed alveolar mucosa to firm and healthy masticatory mucosa took several months (Fig. 4).

Orthodontic movement was terminated after four months, when the marginal soft tissues of the left central incisor reached the level of the gingival margin of the adjacent teeth. A composite pontic was ligated to the arch to provide an esthetic appearance. After two more months of passive retention, the tooth was extracted; the periodontal ligament was still evident on the palatal and approximal aspects of the residual root fragment.

Two months after extraction, the patient underwent surgery for placement of a standard full-size implant in a prosthetically oriented position (Fig. 5). A small fenestration remained where more bone substitute had been removed, but a large bony ridge was available to accom-

modate the coronal portion of the fixture.

The mucogingival junction shifted even more coronally during post-surgical healing, reaching nearly the top of the ridge. The mucogingival defect was corrected in a second surgery, eight months after the first procedure, by means of an apically positioned flap. During that time, the buccal bone generated by the orthodontic movement remained stable. Three weeks after the second procedure, the mucogingival line at the implant site was at almost the same level as on the adjacent teeth. No attempt was made to increase the thickness of the soft tissues around the implant.

After about two months of soft-tissue healing, the prosthodontist inserted a porcelain

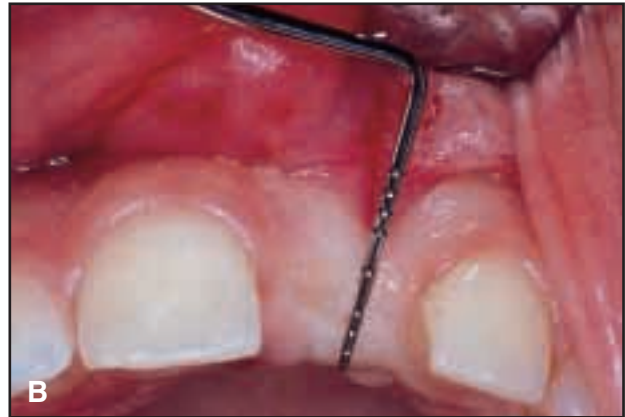
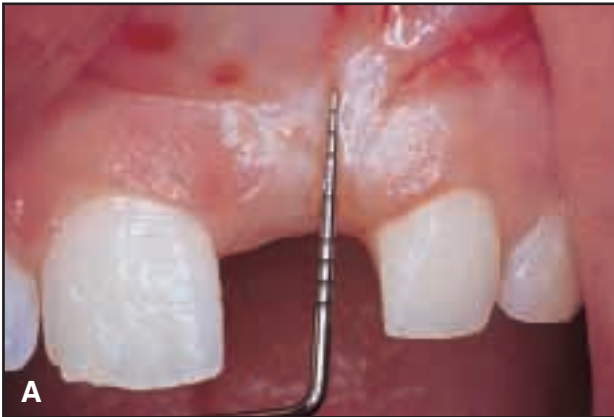
Fig. 4 A. Vertical height of ideal band of masticatory mucosa. B. Required length of displaced masticatory mucosa measured on occlusal.

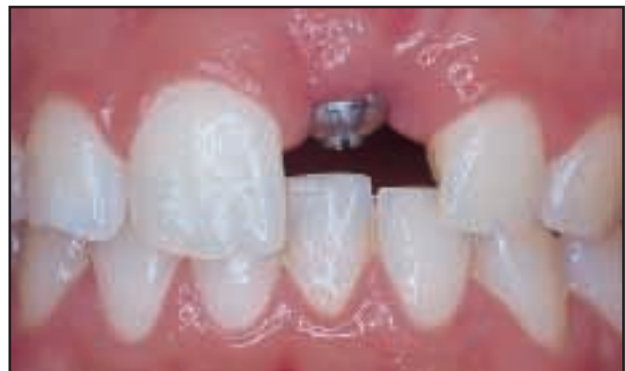
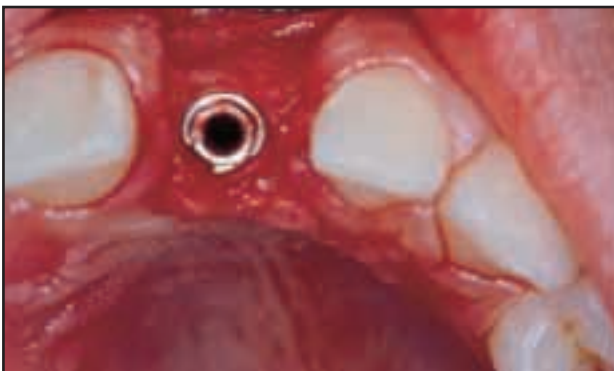
Fig. 5 Full-size implant placed in proper position.

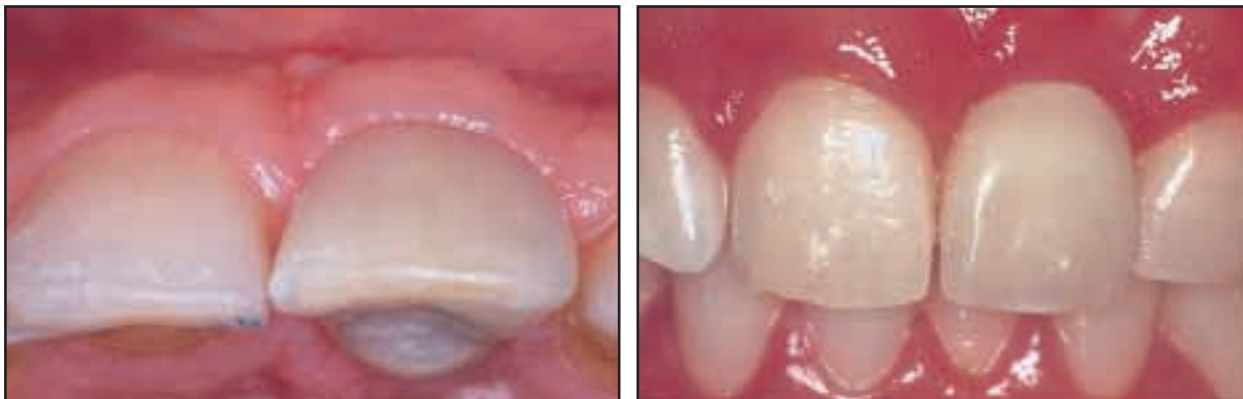

Fig. 6 Porcelain crown two years after implant placement.

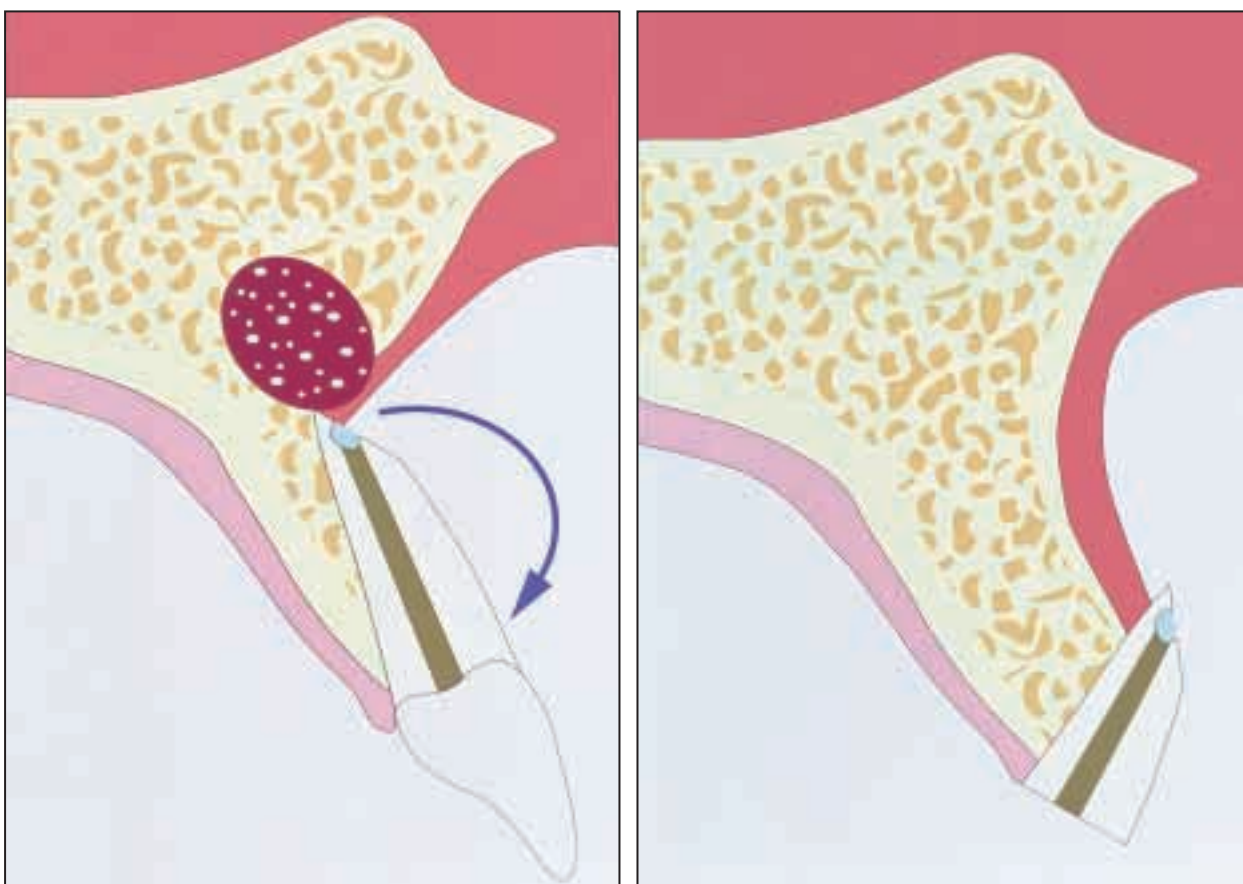


Fig. 7 Effect of buccal root torquing.

crowns. The esthetics met the expectations of the patient. The last follow-up visit showed a pleasant and stable appearance two years after the end of treatment (Fig. 6).

Discussion

In this patient, the complete lack of gingiva associated with a large and deep recession and the periapical foreign-body reaction created a difficult situation. Orthodontic forced eruption provided the required thickness of the bone crest, while the height of gingiva was recovered by an apically positioned flap in the second surgery. The absence of buccal gingiva on the root led to the coronal displacement of the mucogingival junction after the marginal tissues were moved coronally by the orthodontic treatment. Results of this case show that orthodontic movement can be used to enhance the shape of the bony ridge, not only in a coronal direction, but also in thickness, by combining the extrusion with buccal root torque (Fig. 7).

In fact, in every case with a healthy apical residual attachment, enhancement of the implant site was successfully achieved after forced eruption of a tooth with poor prognosis. No bone growth was detected around one tooth where repeated abscesses occurred during treatment. In another case where the periodontal defects reached the apex, the regenerated crest was extremely thin—less than 2mm. Satisfactory bone growth was obtained around another tooth whose attachment loss was beyond the apex on the facial aspect of the root, but where several millimeters of healthy periodontium remained on the other side.

REFERENCES

1. Ingber, J.S.: Forced eruption, Part I: A method of treating isolated one and two wall infrabony osseous defects—rationale and case report, *J. Periodontol.* 45:199-206, 1974.
2. Brown, I.S.: The effect of orthodontic therapy on certain types of periodontal defects, *J. Periodontol.* 44:742-756, 1973.
3. Ingber, J.S.: Forced eruption, Part II: A method of treating non-restorable teeth—periodontal and restorative considerations, *J. Periodontol.* 47:203-216, 1976.
4. Zachrisson, B.U.: Orthodontics and Periodontics, in *Clinical Periodontology and Implant Dentistry*, ed. J. Lindh, T. Karring, and N.P. Lang, 3rd ed., Munksgaard, Copenhagen, 1997, p. 791.
5. Mantzikos, T. and Shamus, I.: Forced eruption and implant site development: An osteophysiologic response, *Am. J. Orthod.* 115:583-591, 1999.
6. Salama, H. and Salama, M.: The role of orthodontic extrusive remodeling in the enhancement of soft and hard tissue profiles prior to implant placement, *Int. J. Period. Restor. Dent.* 13:312-334, 1993.
7. Mantzikos, T. and Shamus, I.: Forced eruption and implant site development: Soft tissue response, *Am. J. Orthod.* 112:596-606, 1997.
8. Barone, R.; Clauser, C.; and Pini Prato, G.: Localized soft tissue ridge augmentation at Phase 2 implant surgery: A case report, *Int. J. Period. Restor. Dent.* 19:141-145, 1999.
9. Cortellini, P.; Bartolucci, E.; Clauser, C.; and Pini Prato, G.P.: Localized ridge augmentation using guided tissue regeneration in humans, *Clin. Oral Implant Res.* 4:203-209, 1993.
10. Zuccati, G. and Bocchieri, A.: Forced eruption of teeth with a poor prognosis and implant site development: Benefits and limits (abstr.), *Eur. J. Orthod.* 24:603-604, 2002.